

IRISH ASSOCIATION FOR
EMERGENCY
MEDICINE



IAEM Clinical Guideline

Peri-capsular Nerve Group (PENG) Block for the Management of Pain in Neck of Femur, Acetabular and Pubic Ramus Fractures

Version 1.1

August 2024

Author: Dr Niall Owens, Dr Cian McDermott

Guideline lead: Dr Cian McDermott, in collaboration with IAEM Guideline Committee

To reference this document please reference as:

Owens N, McDermott C. Peri-capsular Nerve Group (PENG) Block for the Management of Pain in Neck of Femur, Acetabular and Pubic Ramus Fractures. IAEM Guidelines 2024. <https://iaem.ie/professional/clinical-guidelines/> (accessed 27th August 2024).

DISCLAIMER

IAEM recognises that patients, their situations, Emergency Departments and staff all vary. These guidelines cannot cover all clinical scenarios. The ultimate responsibility for the interpretation and application of these guidelines, the use of current information and a patient's overall care and wellbeing resides with the treating clinician.

Revision History

Date	Version	Section	Summary of Changes	Author
May 2023	V1.0	All	Final version	NO
August 2024	V1.1	Contents	Added table of contents	C. Briant

CONTENTS

GLOSSARY OF TERMS	4
PARAMETERS	6
AIMS	6
Figure 1: Surface Anatomy	7
Figure 2: Sonographic Anatomy	7
TECHNIQUE	8
1. Preparation	8
2. Block Technique	8
SPECIAL CONSIDERATIONS	9
REFERENCES	10

GLOSSARY OF TERMS

AIIS	Anterior Inferior Iliac Spine
ASIS	Anterior Superior Iliac Spine
BMI	Body Mass Index
FICB	Fascia Iliaca Compartment Block
In-plane approach	Ultrasound-guided needle manipulation technique in which the entire course of the nerve block needle is visualized in-plane with the ultrasound beam
LA	Local Anaesthetic
LAST	Local Anaesthetic Systemic Toxicity
PENG Block	Peri-capsular Nerve Group Block

Pericapsular Nerve Group (PENG) Blocks for the Management of Pain in Neck of Femur, Acetabular and Pubic Ramus Fractures

INTRODUCTION

Neck of femur fractures, as well as pelvic fragility fractures of the acetabulum and pubic rami, are a common presentation, particularly in the elderly population, in Irish Emergency Departments.¹

The detrimental effects of excessive opioid analgesia in this population are well documented.² Regional anaesthesia planar block techniques such as the Fascia Iliaca Compartment Block have become standard practice in managing these patients and are widely used in the Irish setting.¹ Such techniques are safe and effective when done in the correct setting by appropriately trained personnel in the Emergency Department.⁴

While the efficacy and opioid-sparing effects are well documented, FICB planar block techniques have disadvantages in some patient groups. Recent anatomical research, describing the innervation of the hip joint, indicates that the articular sensory branches of the femoral nerve, obturator nerve, as well as the accessory obturator nerve, may not be completely covered by FICB.³

The PENG block, described in 2018, is thought to offer superior coverage of these terminal sensory branches around the hip joint.⁴ Preliminary research shows that it is non-inferior to FICB.^{5,6} It also has broader coverage of distal pelvic structures such as the acetabulum and pubic rami.⁷

The PENG block also has another advantage over the FICB, in that there is no motor component to the block, as the femoral nerve is avoided. Patients who have a PENG block can safely mobilise afterward.⁷

PARAMETERS

- Target audience: Emergency Physicians who regularly manage patients with neck of femur and pelvic fragility fractures, with competency in ultrasound-guided regional anaesthesia techniques.
- Patient population: Adult patients presenting to the ED with acute neck of femur, acetabular or pubic rami fractures, confirmed either on plain x-ray or CT imaging.
- Exclusion criteria: Inability to provide consent for the procedure.
- Contraindications: Documented allergy to local anaesthetic agent.
Overlying infection at the proposed needle-entry point.
- Relative contraindications: Patients on anti-coagulation or anti-platelet medication, dependent on clinical context and operator experience.

AIMS

This guideline aims to describe the PENG Block as a modality for analgesia in both neck of femur fractures, as well as distal pelvic fractures of the acetabulum and pubic rami. While this guideline outlines the basic technique and procedure of performing this block, further materials, readily available in both video and written format from expert authors, should be reviewed prior to commencing use of this block, as well as instituting a governance structure of its use at local departmental level.

Figure 1: Surface Anatomy

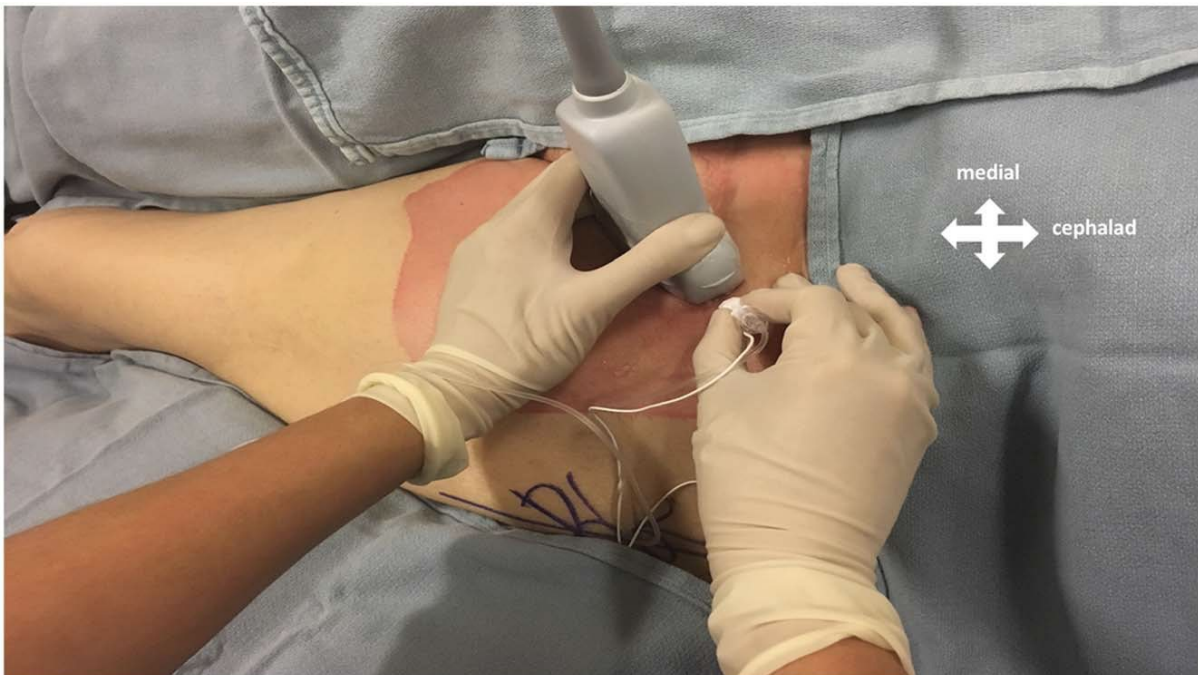
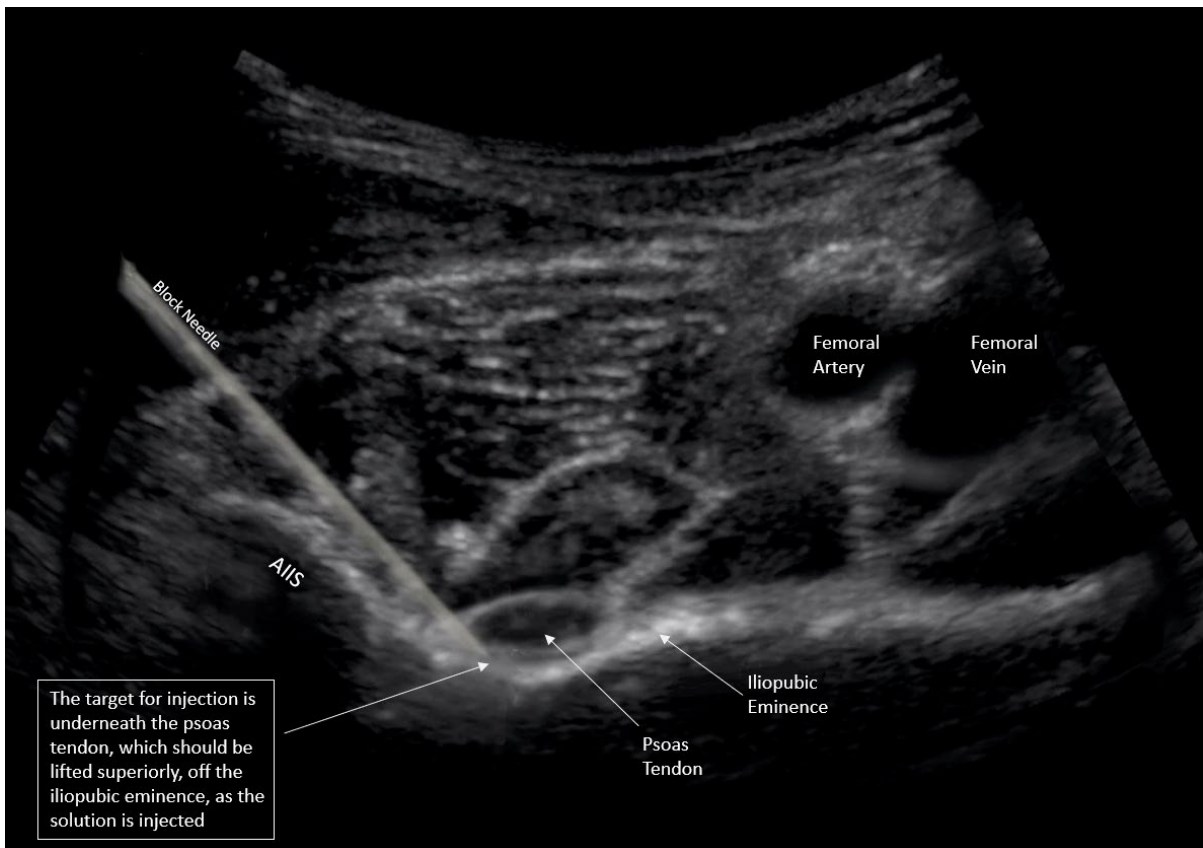


Image from Arango et al. Pericapsular Nerve Group (PENG) Block for Hip Fracture. Regional Anesth Pain Med 2018

Figure 2: Sonographic Anatomy



TECHNIQUE

1. Preparation

- Gather necessary equipment – Either a high frequency linear probe, or curvilinear ultrasound transducer set at close to minimum depth, sterile transducer sheath, 22G block needle with extension tubing and sterile gloves (if available, a dedicated block pack is recommended).
- The proposed block site should be scanned prior to prepping and draping to ensure optimum transducer settings are selected, and relevant anatomy is readily identifiable.
- The chosen local anaesthetic agent is drawn up. For this block, a slightly lower volume than is used for FICB is preferable, due to the smaller anatomic space being targeted. Levobupivacaine 0.5%, with a max dose of 2mg/kg is suggested.
- The proposed injection site and ultrasound probe should be sterilised, prepped and draped as per locally agreed protocol.
- The patient should be placed on monitoring throughout the procedure – 3 lead ECG, SpO₂, and blood pressure measurements cycling at 5 minute intervals.
- Intra-lipid 20% emulsion should be available as an intravenous antidote in the event of local anaesthetic systemic toxicity. Weight-based bolus dose should be calculated ahead of the procedure (1.5ml/kg or 100ml bolus IV) (See IAEM guideline on LAST toxicity here).

2. Block Technique

- Place the transducer in transverse plane over the ASIS.
- Rotate the transducer 45 degrees such that it is in-line with the inguinal crease.
- Slide the transducer medially along this trajectory, toward the pubic tubercle, until the AILS, Iliopubic eminence (IPE) and psoas tendon are identified clearly.

- Insert the block needle lateral-medial, in-plane with the ultrasound field-of-view, maintaining visualization of the needle tip throughout, until the tip rests under the psoas tendon and just superior to the pubic ramus.
- After aspiration to ensure no vascular structure has been punctured, infiltrate the local anaesthetic agent into this space. The psoas tendon should be seen to be lifted superiorly by the injected solution.
- Once the full volume of local anaesthetic is placed, withdraw the needle and apply a standard dressing to the injection site.

SPECIAL CONSIDERATIONS

1. In contrast to other commonly performed regional planar blocks, the curvilinear ultrasound transducer can be used here to maximise the width of the field-of-view and ensure both the femoral vessels, and the AIIIS, can be visualized during the procedure.
2. The angle of insertion of the nerve block needle is steeper than in other blocks to allow passage over the AIIIS and underneath the psoas tendon.
3. The end-point of the needle's trajectory is the pubic ramus, allowing comparatively easier placement in comparison to FICB. However, care must be taken to ensure the local anaesthetic is not injected underneath the periosteum, evident if the resistance to injection is high. If this were the case, the needle should be withdrawn 1-2mm, aspirated again, and injection re-attempted.
4. Similar to other blocks, the dose of local anaesthetic should be reduced by approximately 20% if the patient is known to have renal or hepatic impairment, or a low BMI.
5. Dexamethasone is increasingly used in conjunction with local anaesthetic in peripheral nerve blocks to prolong the duration of efficacy.⁸ A typical dose would be 4mg drawn up and given in the same syringe as the local anaesthetic agent. This should be strongly considered when performing this block.

REFERENCES

1. Ahern, E et al. Irish Hip Fracture Database, National Office of Clinical Audit, 2020 Report
2. Roche JJW, Wenn RT, Sahota O, Moran CG. Effect of comorbidities and postoperative complications on mortality after hip fracture in elderly people: prospective observational cohort study. *BMJ*. 10 dec 2005; 331(7529):1374
3. Short AJ, Barnett JG, Gofeld M, et al. Anatomic Study of Innervation of the Anterior Hip Capsule: Implication for Image-Guided Intervention. *Reg Anesth Pain Med*. 2018;43:186-192.
4. Giron-Arango L, Peng PWH, Chin KJ, et al. Pericapsular Nerve Group (PENG) Block for Hip Fracture. *Regional Anesth Pain Med*. 2018;43:859-863.
5. Morrison C, Brown B, Lin DY, et al. Analgesia and anesthesia using the pericapsular nerve group block in hip surgery and hip fracture: a scoping review. *Reg Anesth Pain Med*. 2021;46:169-175.
6. Fahey A, Cripps E, Ng A, et al. Pericapsular nerve group block for hip fracture is feasible, safe and effective in the emergency department: A prospective observational comparative cohort study. *Emergency Medicine Australasia*. June 2022
7. Cripps E, Fahey A, Snelling P.J. Point-of-care ultrasound-guided pericapsular nerve group block for superior pubic ramus fracture in the emergency department: A case report. *Australas J Ultrasound Med* 2022, 25: 154-156.
8. Huynh, TM, Marret E, Bonnet F. Combination of dexamethasone and local anaesthetic solution in peripheral nerve blocks: A meta-analysis of randomised controlled trials. *European Journal of Anaesthesiology* November 2015 32(11):p 751-758