

IRISH ASSOCIATION FOR
EMERGENCY
MEDICINE



IAEM Clinical Guideline

**Fascia Iliaca Compartment Block for Proximal
Femur Fracture in the Emergency Department**

Version 1.2

August 2024

Author: Ronan Murphy

Guideline lead: Dr Vicky Meighan, in collaboration with the IAEM
Guideline Development Committee and Tallaght Hospital, Dublin,
Ireland.

To reference this document please reference as:

Murphy R. Fascia Iliaca Compartment Block for Proximal Femur Fracture in the
Emergency Department. IAEM Guidelines 2024. [https://iaem.ie/professional/clinical-
guidelines/](https://iaem.ie/professional/clinical-guidelines/) (accessed 27th August 2024)

DISCLAIMER

IAEM recognises that patients, their situations, Emergency Departments and staff all vary. These guidelines cannot cover all clinical scenarios. The ultimate responsibility for the interpretation and application of these guidelines, the use of current information and a patient's overall care and wellbeing resides with the treating clinician.

Revision History

Date	Version	Section	Summary of changes	Author
November 2018	V1.0	All	Final version	RM
April 2019	V1.1	Front cover	Removed guideline number	C. Briant
August 2024	V1.2	All Front cover Contents	Updated formatting Added guideline referencing information Added table of contents	C. Briant C. Briant C. Briant

CONTENTS

GLOSSARY OF TERMINOLOGY AND IMPORTANT POINTS	4
INTRODUCTION	5
PARAMETERS	6
GOALS	7
Figure 1: Surface anatomy	8
Figure 2: Ultrasound anatomy	9
Figure 3: Needle tip placement	10
Figure 4: Post procedure.....	11
Appendix 1: Audit of USS guided Fascia Iliaca Compartment Block	12
Appendix 2: Protocol	13

GLOSSARY OF TERMINOLOGY AND IMPORTANT POINTS

Proximal femur fracture is defined as one involving the proximal one third of the femur and occurs no further distally than 5cm below the lesser trochanter.

Three in one femoral nerve block is a term commonly applied in the literature to a technique where the femoral nerve site is targeted and anaesthetic deposited around same with distal pressure applied circa 30 seconds to aid cephalid spread. It is considered equivalent in effect to the fascia iliaca block in this guideline.

The Obturator Nerve can sometimes be influenced by cephalid spread of anaesthetic. The femoral and lateral cutaneous nerve are influenced by medial and lateral spread respectively as well as cephalid spread toward the lumbar plexus.

Suprainguinal needle insertion has been described however the **infrainguinal** puncture selected in this guideline is better established in the reviewed literature and hence chosen by us as the technique of choice at the current time.

An indwelling catheter was declined for introduction at the present moment as it requires additional training and experience. This will be reviewed in future editions of this guideline.

In plane ultrasound approach was selected in consultation with the department of anaesthesia as it offers full visualization of the block needle track.

Fascia Iliaca Compartment Block for Proximal Femur Fracture in the Emergency Department

INTRODUCTION

According to the Irish Hip Fracture Database figures published in November 2016, there are 3,591 hip fractures per annum in Ireland and the majority of these occur in patients aged 60 years or older.

The block makes use of an anatomical compartment (see figure below) to act as the conduit via which to deliver local anaesthetic to the nerves of the lumbar plexus supplying the hip joint. These nerves are the lateral cutaneous nerve, the femoral nerve and the obturator nerve. Since this is a compartment block, filling a potential space beneath the fascia iliaca, a large volume is employed (40-50mls commonly) to assure adequate spread of the agent in all directions. The use of 0.25% Levobupivacaine facilitates this. After a successful block, the subsequent requirement for opioids is reduced which avoids potential side effects especially in older patients.

Inadequately treated pain from hip fractures has been associated with adverse patient outcomes such as pneumonia and potentially others such myocardial ischemia as well as an overall increased mortality.

The block lends itself as an effective mode of analgesia in the Emergency Department setting with its rapid onset within 30 min and long duration of action averaging to eight-nine hours post administration.

The literature supports that a correctly placed injection should have very little chance of intravascular injection or neural injury as we are targeting are between these structures and obtaining effects via regional spread.

PARAMETERS

Target audience: Registrars and Consultants in Emergency Medicine

Patient population: Those with a proximal femur fracture requiring preoperative analgesia.

The technique is best established in adult patients, however, for appropriately trained experienced practitioners, the block has a role in paediatric fracture management also. Our guideline is written specifically for application in the Adult Emergency Department.

Contraindication: patient refusal, known allergy or hypersensitivity to agent used, infection over injection site and severe coagulopathy.

Relative contraindications: patients on anticoagulation or antiplatelet therapies depending on operator experience and clinical context.

Counselling points: Risk of failure is common between 1/10 and 1/100. Haemorrhage, nerve damage, local anaesthetic systemic toxicity are rare complications between 1/1000 and 1/10,000 cases.

GOALS

The protocol ([Appendix 2](#)) below gives the operator a standardized approach to performing this block under ultrasound guidance.

It is recommended to be used as a challenge-response checklist.

The topic of local anaesthetic systemic toxicity is addressed and safeguarding to permit early recognition of same. The importance of aseptic technique as per your institutions standard practices when performing this block needs to be emphasized.

We constructed a protocol in cooperation with our stakeholders in the Department of Anaesthesia and the Department of Orthopaedics. We studied the introduction of the protocol at our centre ([Appendix 1](#)) pre and post staff education program.

We employed the use of Levobupivacaine rather than the mixture of lignocaine and Levobupivacaine, as it allows maximal safe dosing of the longer acting agent and there is minimal difference in the duration of onset. In our study below and in our protocol, we assess post block analgesic effect at 30 minutes but the literature supports onset of analgesia within 10 minutes with Levobupivacaine.

Figure 1: Surface anatomy

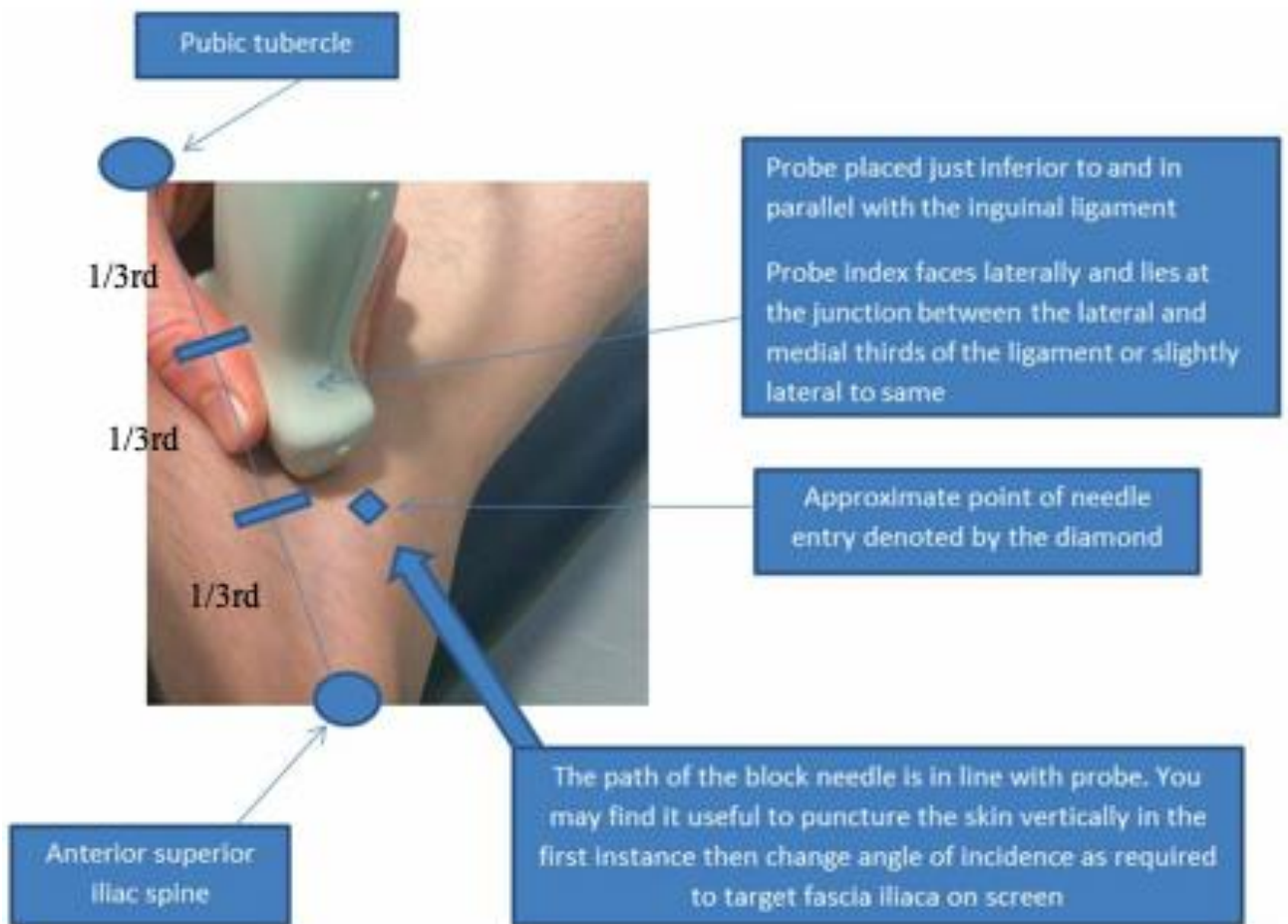


Figure 2: Ultrasound anatomy

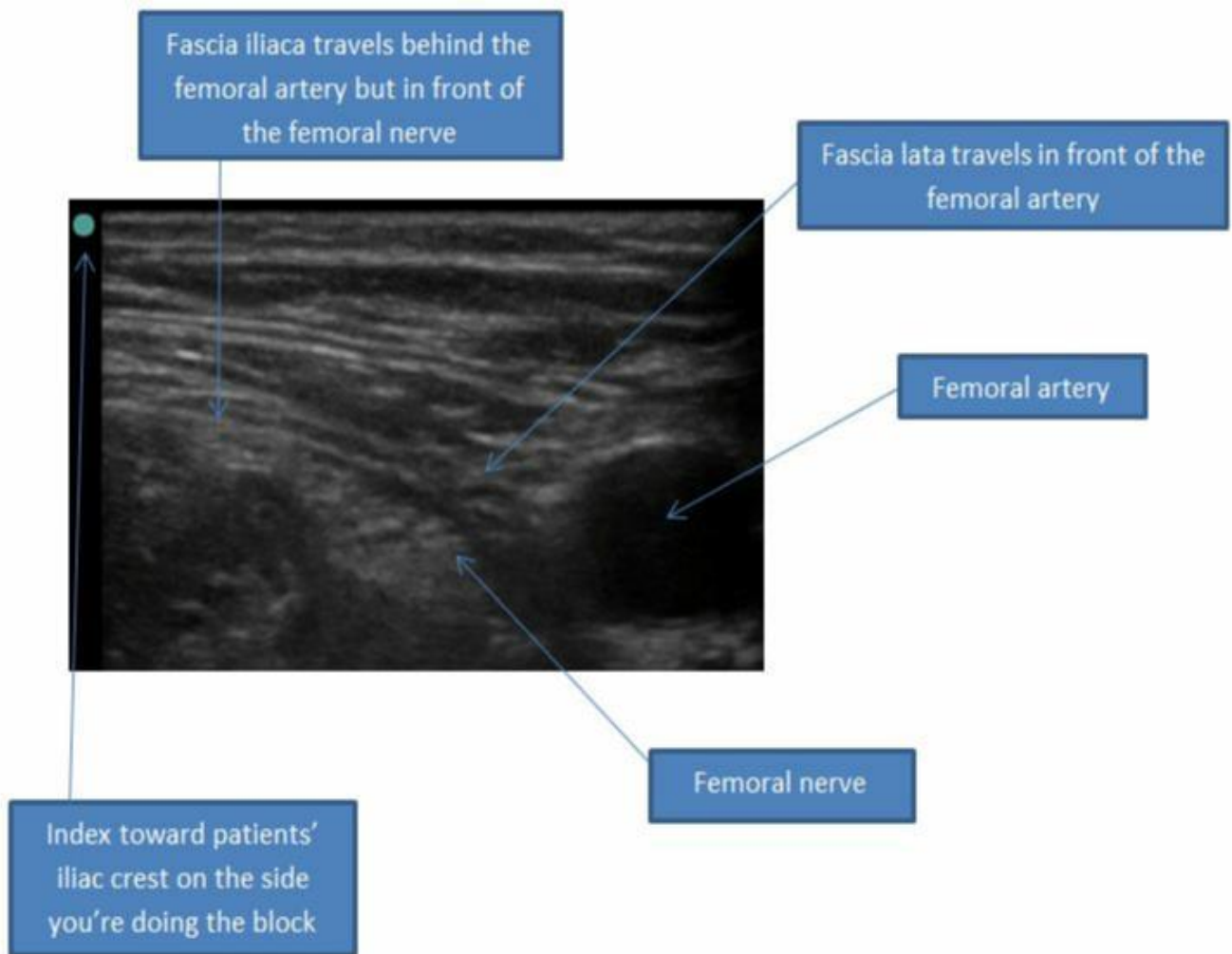


Figure 3: Needle tip placement

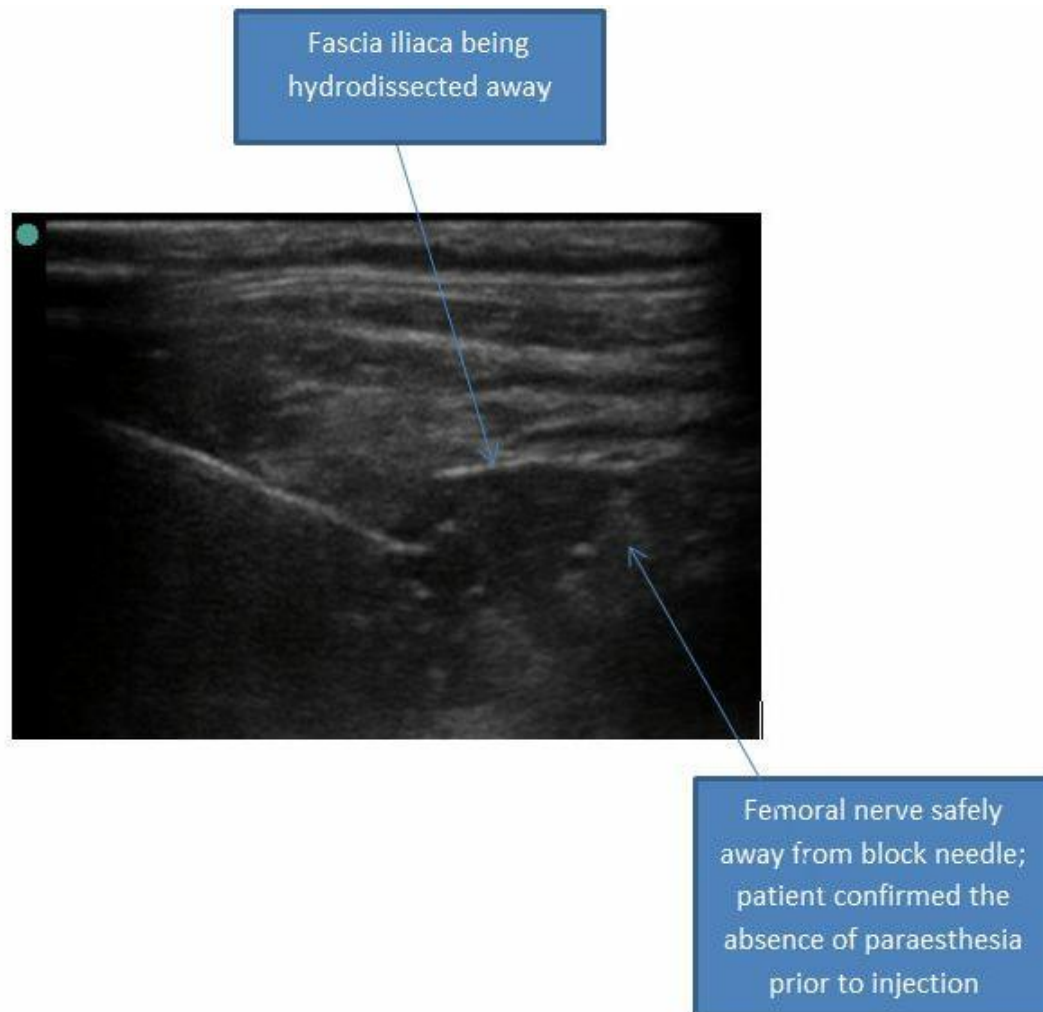
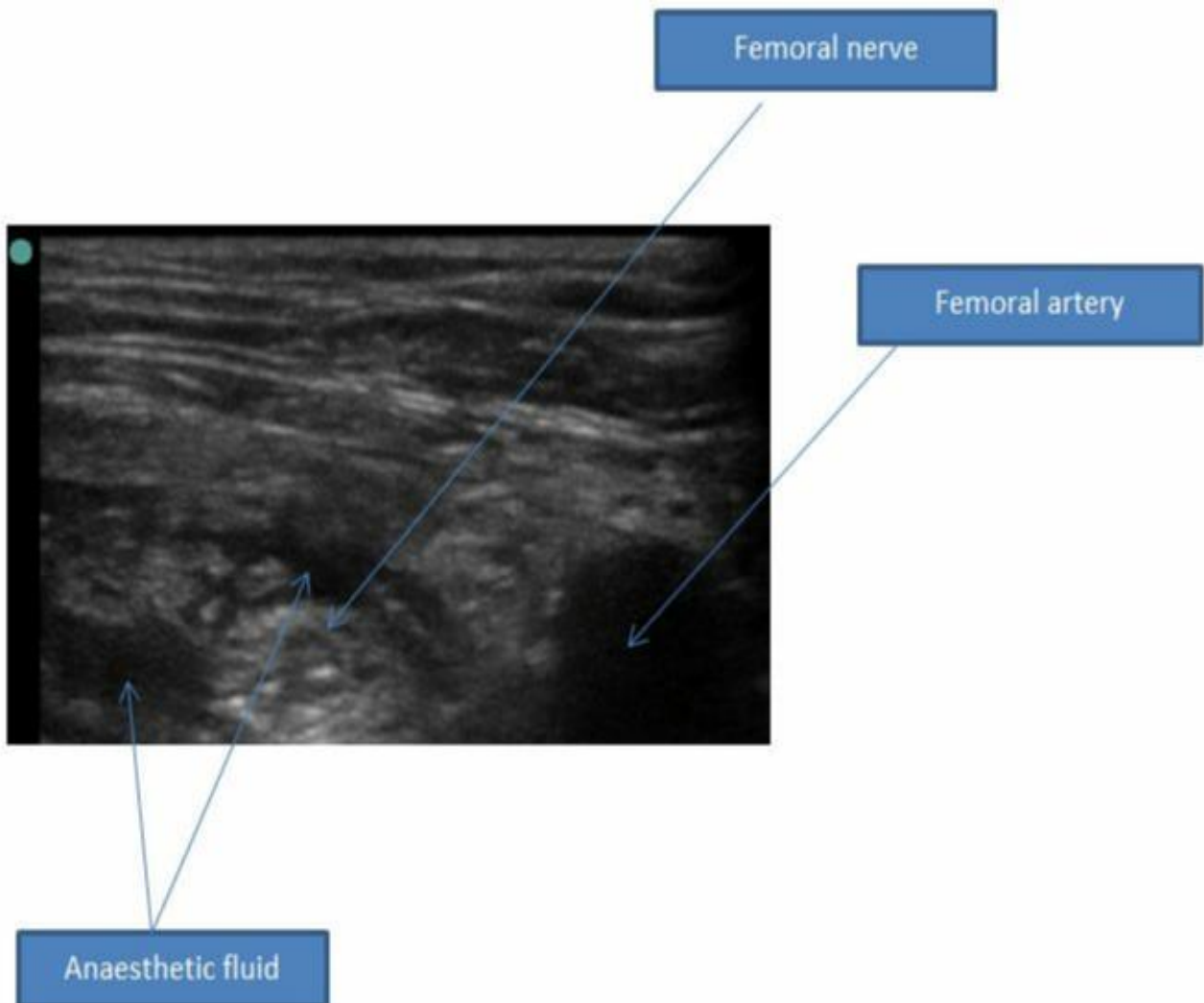


Figure 4: Post procedure



Appendix 1: Audit of USS guided Fascia Iliaca Compartment Block

Introduction of USS guided Fascia Iliaca Compartment block to Tallaght ED

Murphy R, Meighan V

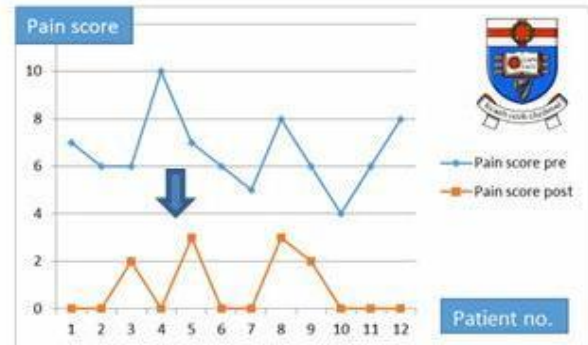
Introduction:

We saw 152 proximal third of femur fractures last year with an average age of 75 years old making these persons particularly susceptible to opiate side effects and pain related delirium. There is a real demand for alternative and effective long acting analgesia in the ED for these patients.

We audited the effectiveness of a one morning education session plus a new checklist protocol on the uptake and success of the block over 2 months.

Results:

Average was 76 years old. 12 out of the 22 cases which presented received the block. No blocks for same number of presentations in the 2 months prior. Mean duration of block was 8.5 hours. One patient was on warfarin with an INR of 3.5. Another was on Abciximab. There were no complications. Cost per block is twenty euro.



Conclusions:

All patients had pain scores reduced to the non opioid requiring (WHO pain score less than five) category. A little training goes a long way with this block. Although it is more expensive than providing parenteral opiates, the block has advantages for the patient in terms of sustained pain relief and avoidance of opiates.

Appendix 2: Protocol

Full size printable protocol is on next page.

We recommended that a designated trolley to be established in each Emergency Department to facilitate the performing of this procedure.

The trolley should contain a regularly replenished supply of all consumables used in the protocol below.

Essential to the safety of this procedure is that operator should always keep the position of their block needle tip in sight.

If you experience excessive resistance on injection you may be injecting intramuscularly rather than into the potential space behind the fascia iliaca overlying iliacus muscle. Look for spread of local anaesthetic on screen and confirm needle tip position.

**Ultrasound Guided Fascia Iliaca Block for
Confirmed Fractures of the Proximal Third of Femur**
For use by Registrars/Consultants in Emergency Medicine



**TALLAGHT HOSPITAL
EMERGENCY
DEPARTMENT**



DOCUMENT

- Exclude contra-indications (patient declines, allergy to local anaesthetic, severe coagulopathy, infection at injection site)
- Informed verbal consent (explain risk of failure, soft tissue infection, vascular puncture and nerve injury)
- Pre-procedure pain score:
0 1 2 3 4 5 6 7 8 9 10

PREPARE

- Drugs: 0.6 ml/kg of Levobupivacaine 0.25% (max dose 2mg/kg and 60mls) using 20ml syringes
[50kg=30mls ; 55kg=33mls ; 60kg=36mls ; 65kg=39mls ; 70kg=42mls ; 75kg=45mls ; 80kg=48mls]
Assemble 20 ml syringe to the short blunt bevel needle with flexible extension lead (24g/2 inch plexufix)
- Equipment: Dressing pack, chlorhexidine skin prep, USS machine, sterile USS probe covers, 20 ml syringes +/- Local anaesthetic, sterile gloves
- The patient - supine position, prepare aseptic field

STOP BEFORE YOU BLOCK - Ensure two staff members confirm the correct side

BLOCK

- Identify the anatomy using linear USS probe on nerve setting
- Scan transversely the inguinal crease
- Identify the femoral artery and slide the probe laterally to identify the fascia iliaca, iliacus muscle and fascia lata covering sartorius muscle
- Using a needle in plane technique aspirate before instilling 2mls Levobupivacaine slowly under fascia iliaca, check spread, aspirate after every 5 mls injected.
- Withdraw needle and cover site with a plaster

DOCUMENT

- The procedure – drugs used and time of instillation
- Post-procedure pain score at 30 mins - if block has failed, give alternative analgesia, do not repeat it
0 1 2 3 4 5 6 7 8 9 10

MONITOR

ECG/BP/SPO2 for 30 mins

Look for signs of local anaesthetic toxicity :

CNS: perioral paraesthesia, slurred speech, confusion, coma, seizures

RESP: methaemoglobinaemia

CVS: tachycardia, hypertension, hypotension, arrhythmia

GI: nausea and vomiting

Management of Local Anaesthetic Toxicity

STOP – the procedure/LA infiltration

MOVE – the patient to resus and get senior help

ASSESS ABCDE

ECG - if prolonged QRS give sodium bicarbonate 8.4% IV

- if torsades de pointes give magnesium 2g IV over 30 mins

TREAT Hypotension with IV fluid boluses

TREAT Seizures with lorazepam 4mg IV

Consider Intralipid emulsion 20% IV - 1.5ml/kg bolus then infusion 0.5ml/kg/min for 30 mins (max 500ml)

Stored in the drug room fridge and theatre

Authors Dr Vicky Meighan, Dr Pat Conroy, Dr Ronan Murphy

Created July 2015 Revised August 2018