

IRISH ASSOCIATION FOR  
EMERGENCY  
MEDICINE



IAEM Clinical Guideline

## Emergency Department Management of Blunt Chest Wall Injuries

Version 1.1

August 2024

Authors: Dr. Saema Saeed, Dr. Conor Deasy, Dr. Darren McLoughlin, Ms. Avril Hallahan.

Guideline Leads: Dr. Conor Deasy, in collaboration with IAEM Clinical Guideline Committee and Cork University Hospital.

### To reference this document please reference as:

Saeed S, Deasy C, McLoughlin D, Hallahan A. Emergency Department Management of Blunt Chest Wall Injuries. IAEM Guidelines 2024. <https://iaem.ie/professional/clinical-guidelines/> (accessed 27<sup>th</sup> August 2024).

### DISCLAIMER

IAEM recognizes that patients, their situations, Emergency Departments, and staff all vary. These guidelines cannot cover all clinical scenarios. The ultimate responsibility for the interpretation and application of these guidelines, the use of current information and a patient's overall care and wellbeing resides with the treating clinician.

## Revision History

Date	Version	Section	Summary of changes	Author
August 2021	V1.0	All	Final version	SS/CD/ DMcL/AH
August 2024	V1.1	All Front cover References	Updated formatting Added guideline referencing information Added references to main document	C. Briant C. Briant C. Briant

## CONTENTS

GLOSSARY OF TERMS .....	4
PARAMETERS.....	5
AIM .....	5
INTRODUCTION .....	6
INVESTIGATIONS.....	8
MANAGEMENT .....	9
ANALGESIA.....	10
Chest Injury Score.....	10
Systemic analgesia .....	11
Regional anaesthesia.....	11
Non-pharmacological management .....	12
DISPOSITION.....	12
Admission .....	12
Discharge.....	13
COMPANION DOCUMENTS.....	13
REFERENCES .....	14

## GLOSSARY OF TERMS

ACBT	Active Cycle of Breathing Techniques
CDU	Clinical Decision Unit
CPAP	Continuous Positive Airway Pressure
CTS	Cardiothoracic Surgery
CXR	Chest X-ray
DC	Discharge
ED	Emergency Department
FBC	Full Blood Count
FITT	Frailty Intervention Team and Therapists
ITU	Intensive Trauma Unit
NIV	Non-Invasive Ventilation
PCA	Patient Controlled Analgesia
PVB	Paravertebral Block
SaO <sub>2</sub>	Oxygen Saturation
RTC/MVA	Road Traffic Collision/Motor Vehicle Accident
TE	Thoracic Epidural

## PARAMETERS

### Target audience

- All healthcare professionals who provide clinical care to patients who present in the acute setting with chest wall injury.

### Patient population

- Adults ( $\geq 16$  years old) who present to the ED with chest wall injury.

### Exclusion criteria

- Age less than 16
- Atraumatic chest pain

## AIM

- To introduce a chest injury pathway for all staff involved in the care of patients with chest wall trauma with particular relevance to those working in Emergency Departments and Injury Units across Ireland.
- To improve the quality, continuity, and co-ordination of care across different departments and reduce morbidity and mortality by managing chest wall trauma proactively.

# Emergency Department Management of Blunt Chest Wall Injuries

## INTRODUCTION

The ribs are the most commonly injured component of the thoracic cage. The morbidity and mortality results from poor analgesia, inadequate physiotherapy and respiratory support, leading to splinting of the thorax, atelectasis and pneumonia, resulting in impaired ventilation and oxygenation. This risk rises substantially with advancing age and pre-existing lung disease. While patients with rib fractures may appear well initially, they typically deteriorate 24-48 hours later.

The presence of multiple rib fractures in a young patient may imply a greater transfer of force than in older patients. Conversely, the presence of rib fractures in older patients should be of concern, as the risk of complications, specifically, death from respiratory sepsis is much higher.

NOTE: Although most patients present with a history of trauma, some, particularly the frail older patient might present with an episode of collapse and be referred to medical teams. Chest wall injury might be missed in this cohort.

## CLINICAL

Causes:

- Blunt trauma including MVAs, assault and falls.
- 'Low falls' in the older population
- Coughing spells.
- Domestic violence/Elder Abuse.

Symptoms:

- Pain that worsens on movement or palpation of the torso, or movement of the arms.
- Pain that increases on breathing deeply, sneezing, or coughing (pleuritic).
- Shortness of breath.
- Haemoptysis.

Signs:

- Hypoxia, cyanosis, and respiratory distress.
- Tachypnoea and use of accessory muscles.
- Haemodynamic instability.
- Palpable or visible deformity and paradoxical chest movements.
- Bruising/Seat belt marks.
- Localized pain and tenderness on palpation.
- Skin crepitus.

Complications:

- Flail chest affect respiratory mechanics and cause increased work of breathing.
- Haemothorax, pneumothorax.
- Pulmonary contusions and lacerations (contusions evolve over the first 48-72 hours).
- Superior vena caval obstruction.
- Hepatosplenic injury - high degree of suspicion in lower rib fractures.
- Cardiac contusions.
- Mediastinal / Great vessel injury - particularly fractures of the scapula, first or second rib, or the sternum suggest a significant force of injury.
- Extrapleural haematoma.
- Oesophageal injury, diaphragmatic injury.

- Atelectasis and pneumonia, which can be a consequence of inadequate analgesia and sputum clearance.

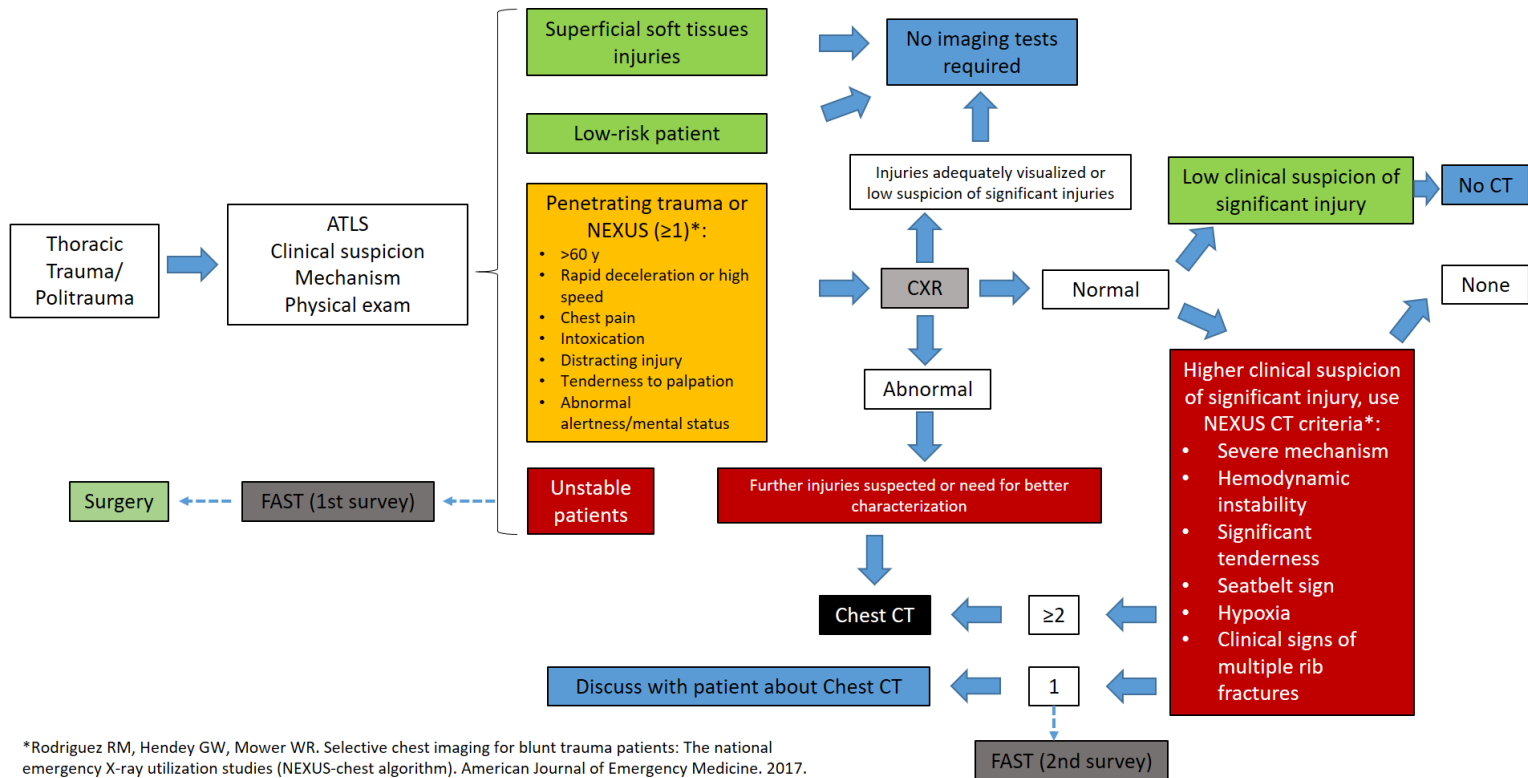
## INVESTIGATIONS

- **Point of Care Ultrasound** by a trained practitioner is a useful tool in identifying life-threatening injuries at the bedside e.g. cardiac tamponade, massive haemothorax, pneumothorax and intra-abdominal fluid. It has the advantage of being easy to repeat while the patient is in the ED, thus allowing for frequent reassessment.
- **ECG** should be done to identify any underlying cardiac injury.
- **Blood tests** including FBC, U+E, LFTs, Coagulation, Fibrinogen, Blood gas, Group and hold / cross-match, Troponin (if cardiac contusion suspected).
- **Chest X-ray** is an easily accessible, quick investigation, which can be done in the resuscitation room if necessary. It risks missing some injuries and may underestimate the extent of the injuries but it allows early identification of life-threatening injuries such as massive haemothorax, pneumothorax, and flail chest.
- **CT Thorax** is indicated in any patient in whom you suspect significant chest wall injury or underlying lung or mediastinal injury. It may help guide further management. It involves moving the patient to CT and the patient should be stabilised and life-threatening injuries should be dealt with prior to transfer.

The [NEXUS Chest decision instrument for blunt trauma](#) and the [Nexus Chest CT decision instrument](#) are online tools that can be used to guide investigations.



**Table 1. Below can be used to guide diagnostic management of thoracic trauma.**



## MANAGEMENT

The initial goal in the ED is assessment and stabilisation based on the ABCDE approach (ATLS).

Once life-threatening injuries are addressed and the patient is stabilised, the secondary survey can be undertaken.

## ANALGESIA

Pain relief is essential for patient comfort, but also to allow adequate ventilation and prevent atelectasis and infection.

This can be achieved by systemic analgesia, regional anaesthesia and non-pharmacological techniques.

A chest injury score (STUMBL Score) can help guide management.

For the chest injury score / calculator, which was designed and developed by Dr. Íomhar O'Sullivan, Consultant Emergency Medicine, Cork University Hospital, please refer to the following link: [http://emed.ie/Trauma/Chest/Rib\\_Fractures.php](http://emed.ie/Trauma/Chest/Rib_Fractures.php)

### Chest Injury Score

• Age: for each 10 years over age 10	+ 1	=
• Rib fractures: for each individual fracture (flail rib = +6)	+ 3	=
• Chronic lung disease	+ 5	=
• Anticoagulant or Antiplatelet (except aspirin)	+ 4	=
• SaO <sub>2</sub> at room air: for each 5% fall below 95%	+ 2	=
TOTAL SCORE		=

Score 0 - 10 'Conservative'	•Regular Paracetamol +/- NSAID •Oral Opioid/Lidocaine Patch
Score 11-20 'Progressive'	•As Above •IV PCA +/- Paravertebral Block if unable to cough or deep breathe
Score 21 - 30 'Aggressive'	•As Above + Paravertebral Block •Consider CPAP (Move patient into Resus)
Score >31 'Emergent'	•As Above + Paravertebral Block/Epidural •If flail segment/multiple bilateral rib fractures - CTS RV

## Systemic analgesia

A pain score should be recorded, and the appropriate analgesia administered.

Refer to IAEM guideline <http://www.iaem.ie/wp-content/uploads/2019/04/IAEM-CG-ED-Analgesia-in-Adults.pdf> for further guidance. The response to analgesia should be assessed frequently.

Patients may require regular opioids and a Patient Controlled Analgesia (PCA) pump should be considered.

Lidocaine patches may be a useful adjunct (off license).

## Regional anaesthesia

Regional anaesthesia is recommended for patients who have multiple rib fractures and/or those in whom multimodal analgesia is ineffective.

Ultrasound guided Serratus Anterior Plane Blocks <https://iaem.ie/wp-content/uploads/2020/02/IAEM-Clinical-Guideline-SAPB.pdf> or Erector Spinae Plane Blocks are being performed in some EDs and are an effective way of providing pain relief for 8-12 hours.

In some hospitals, the Pain Team are available for intercostals blocks, epidural blocks or paravertebral blocks and may offer the option of catheter insertion so that the block can be topped-up as required.

## Non-pharmacological management

Physiotherapy should be started within 24 hours of admission in all patients to support ventilation and prevent complications. It includes a combination of techniques optimised to each patient. Adequate analgesia is recommended to allow for effective and aggressive physiotherapy (Lovisari et al, 2020).

### Aims of Physiotherapy are:

- Adequate humidification of airways
- Mobilisation and removal of retained secretions and augmentation of cough effort
- Improving oxygenation
- Increasing and restoring lung capacity, volume, and compliance
- Improving respiratory muscle strength
- Prevention of joint stiffness
- Restoring independence in functional activities

## DISPOSITION

### Admission

Admit any patient with significant chest wall trauma with one or more of the following features

- Frailty and/or social issues.
- Significant co-morbidities.
- Pain not controlled with conventional analgesia.
- Respiratory compromise or flail chest.
- Multiple injuries.

Monitor oxygen saturations, pain scores, analgesia requirements and NEWS scores in admitted patients regularly. If these are deteriorating, consider repeating a CXR and request senior or specialist review.

If pain is controlled but SaO<sub>2</sub> is decreasing, repeat CXR and consider NIV or nasal high flow, as well as ICU support and CTS/Surgical review.

The chest injury score can also be used to guide admission, but this will also depend on the presence of other injuries, clinical judgement, and availability of specialist teams.

## Discharge

Patients with simple rib fractures whose pain is controlled on oral / topical analgesia may be discharged home with appropriate safety netting.

They should receive written advice on management and prognosis with clear guidance on when to return. An example of an appropriate advice sheet can be found [here](#).

## COMPANION DOCUMENTS

1. [CUH Adult Chest Wall Injury Pathway](#)
2. [Advice sheets for patients](#)

## REFERENCES

- Battle C, Hutchings H, Lovett S, et al. - Predicting outcomes after blunt chest wall trauma: development and external validation of a new prognostic model.  
<https://doi.org/10.1186/cc13873>
- Dr Ben Warrick, Clinical Lead Major Trauma - Adult Chest Wall Injury Pathway - Royal Cornwall Hospitals <https://doclibrary-rcht.cornwall.nhs.uk/GET/d10346359>
- Robin Berry, Mark Rocket, Kate Sharpe - Chest Injury - University Hospitals Plymouth NHS Trust  
<https://www.plymouthhospitals.nhs.uk/download.cfm?doc=docm93jjm4n1277.pdf&ver=1525>  
<https://www.plymouthhospitals.nhs.uk/download.cfm?doc=docm93jjm4n1277.pdf&ver=1525>
- Carlos Galvez, Juan Arenas-Jimenez, Jone Del Campo, Sergio Maroto, Marina Sirera, Francisco Lirio - Diagnostic imaging pathways in the setting of acute chest wall trauma <http://jovs.amegroups.com/article/view/34041/html>
- Cordelie E Witt, Eileen M Bulger - Comprehensive approach to the management of the patient with multiple rib fractures: a review and introduction of a bundled rib fracture management protocol <https://tsaco.bmj.com/content/2/1/e000064>
- Dr A Qureshi, Mrs L Wilkinson, Mr R Clymer, Mrs C Wade, Dr S Platt - Newcastle upon Tyne Hospitals NHS Foundation Trust | Chest Trauma Guideline  
<https://nusgra.co.uk/chesttrauma.pdf>
- Ian Sinha, Alex Wickham & Sabeena Qureshi - Imperial College Healthcare Rib Fracture Guideline <http://smh-gas.org.uk/wp-content/uploads/2016/12/Rib-fracture-guideline.pdf>
- Robert M. Rodriguez, Mark I. Langdorf, Daniel Nishijima, Brigitte M. Baumann, Gregory W. Hendey, Anthony J. Medak - Diagnostic management of thoracic trauma.

ATLS, Advanced Trauma Life Support; NEXUS, National Emergency X-radiography Utilization Studies; CXR, chest X-ray; CT, computed tomography; FAST, focused assessment in sonography for trauma.

[https://www.researchgate.net/publication/282904885\\_Derivation\\_and\\_Validation\\_of\\_Two\\_Decision\\_Instruments\\_for\\_Selective\\_Chest\\_CT\\_in\\_Blunt\\_Trauma\\_A\\_Multicenter\\_Prospective\\_Observational\\_Study\\_NEXUS\\_Chest\\_CT](https://www.researchgate.net/publication/282904885_Derivation_and_Validation_of_Two_Decision_Instruments_for_Selective_Chest_CT_in_Blunt_Trauma_A_Multicenter_Prospective_Observational_Study_NEXUS_Chest_CT)

- K. El-Boghdady M. D. Wiles - Regional anaesthesia for rib fractures: too many choices, too little evidence. <https://doi.org/10.1111/anae.14634>
- Gosselink, R., Bott, J., Johnson, M., Dean, E., Nava, S., Norrenberg, M., Schonhofer, B., Stiller, K., van de Leur, H. & Vincent, J. L. (2008) “Physiotherapy for adult patients with critical illness: recommendations of the European Respiratory Society and European Society of Intensive Care Medicine Task Force on Physiotherapy for Critically Ill Patients”, *Intensive Care Medicine*, 34(1188-1199).
- Lovisari, F., Favarato, M., Giovannini, I., Giudici, R. & Fumagalli, R. (2020) “Chest wall pain management after chest wall trauma”, *Journal of Visualized Surgery*, 6:18.
- Sharma, O.P., Oswanski, M.F., Jolly, S., Lauer, S.K., Dressel, R. & Stombaugh, H.A.(2008) “Perils of rib fractures”, *The American Surgeon*, 74(4):310–314.
- Sum, S.K., Peng, Y.C., Yin, S.Y., Huang, P.F., Wang, Y.C., Chen, T.P., Tung, H.H. & Yeh, C.H. (2019) “Using an incentive spirometer reduces pulmonary complications in patients with traumatic rib fractures: a randomized controlled trial”, *Trials*, 20 (797).
- Van Aswegen, H. (2020) “Physiotherapy management of patients with trunk trauma: A state-of-the-art review”, *South African Journal of Physiotherapy*, 76(1), a1406.
- Van Aswegen, H., Reeve, J., Beach, L., Parker, R. & Fagevik Olsén, M. (2019) “Physiotherapy management of patients with major chest trauma: Results from a global survey”, *Trauma*, 22(2), 133–141.

- Northern Devon Healthcare NHS Acute Pain Guidelines Jan 2017.

<https://www.northdevonhealth.nhs.uk/wp-content/uploads/2017/06/Acute-Pain-Guidelines-v3.0.pdf>