

IRISH ASSOCIATION FOR
EMERGENCY
MEDICINE



IAEM Clinical Guideline

**Cervical Lymphadenopathy: Initial management
in an Acute Paediatric Setting**

Version 1.1

September 2024

Authors: Dr. Anna O’Leary, Dr. Roisin McNamara, Ms. Mary Worrall, Dr. Sheena Durnin, Dr. Cormac Breathnach, Dr. Carol Blackburn

Guideline leads: Dr. Carol Blackburn in collaboration with CHI Guideline Development Committee, CHI Crumlin, CHI Temple Street , CHI Connolly and IAEM Clinical Guideline Committee

To reference this document please reference as:

O’Leary A, McNamara R, Worrall M, Durnin S, Breathnach C, Blackburn C. Cervical Lymphadenopathy: Initial management in an Acute Paediatric Setting. IAEM Guidelines 2024. <https://iaem.ie/professional/clinical-guidelines/> (accessed 2nd September 2024).

DISCLAIMER

IAEM recognises that patients, their situations, Emergency Departments and staff all vary. These guidelines cannot cover all clinical scenarios. The ultimate responsibility for the interpretation and application of these guidelines, the use of current information and a patient’s overall care and wellbeing resides with the treating clinician.

Revision History

Date	Version	Section	Summary of changes	Author
February 2021	V1.0	All	Final Version	AO'L/RMcN/ MW/SD/CB/ CB
September 2024	V1.1	All Front cover Contents	Updated formatting Added guideline referencing information Added table of contents	C. Briant C. Briant C. Briant

CONTENTS

INTRODUCTION	5
PARAMETERS	6
AIMS	6
ASSESSMENT	7
MANAGEMENT	8
Investigations	8
Figure 1: Flowchart of the Management of patient with Cervical Lymphadenopathy	9
Imaging.....	10
Treatment: Acute Adenitis.....	11
REFERENCES	11

GLOSSARY OF TERMS

CMV	Cytomegalovirus
CXR	Chest X-ray
ED	Emergency Department
EBV	Epstein-Barr Virus
ENT	Ear Nose and Throat
HIV	Human Immunodeficiency Virus
ID	Infectious Disease
NHL	Non-Hodgkin Lymphoma
TB	Tuberculosis
SLE	Systemic Lupus Erythematosus
US	Ultrasound

Cervical Lymphadenopathy: Initial Management in an Acute Paediatric Setting

INTRODUCTION

Cervical lymphadenopathy is the most frequent cause of neck lumps in children. It ranges from benign and self-resolving to malignant. It affects 90% of children aged 4-8 years. It is generally agreed that cervical lymphadenopathy or adenopathy refers to a node >1cm in diameter.¹ Enlarged nodes are common with viral infections. Such 'reactive' lymph nodes are usually small, firm and non-tender. They may persist for weeks or months and do not require investigation.²

Most cervical lymphadenopathy in otherwise healthy children is due to infection.³ Other cause of cervical lymphadenopathy includes bacterial infection, Kawasaki disease, viral infection, malignancy and rheumatological condition such as Juvenile arthritis and SLE. Persistent lymphadenopathy will need further investigation, especially when the patient is unwell and associated with other symptoms. Therefore a systematic approach to diagnosis and evaluation must be considered when dealing with patient with cervical lymphadenopathy.

PARAMETERS

Target audience This guide is directed at healthcare professionals involved in evaluating children in Acute Paediatric Services - ED or Urgent care - with cervical lymphadenopathy. This guideline may also be of use in a general paediatric outpatient setting.

Patient population This evidence summary applies to evaluating children in Acute Paediatric Services- ED or Urgent Care- with cervical lymphadenopathy.

Exclusion criteria Patient population >16 years of age.
Patient with airway compromise.

AIMS

1. To offer evidence-based guidance for management of children presenting with acute cervical lymphadenopathy.
2. To indicate where investigations are needed, if any, and inform which children need onward referral.

ASSESSMENT

Take a history and perform a full examination.

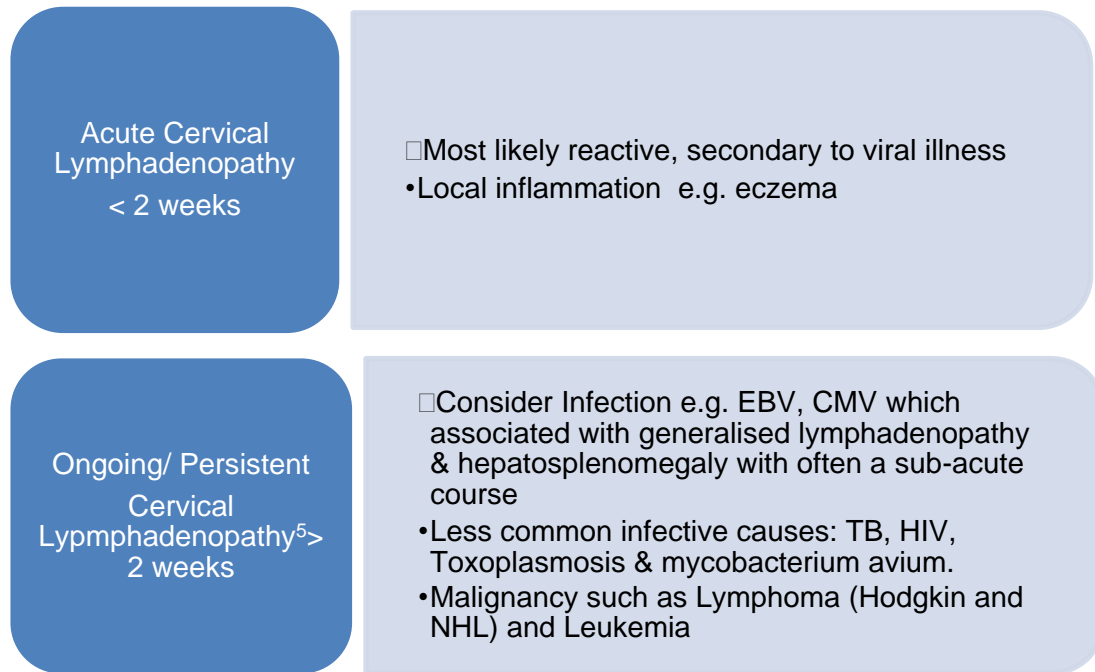
Note especially the following:

- Duration: acute <2 weeks, persistent >2 weeks. Please see flowchart in figure 1 for next steps.
- Size of nodes
- Physical exam findings such as tachypnea, pallor, petechiae, hepatomegaly and splenomegaly
- History of lethargy or weight loss
- Associated systemic signs, fever, overlying erythema/ cellulitis, dental signs

Red Flags

- Size **greater than 2 cm**
- Size ≤ 2 cm with inflammatory signs and no improvement with appropriate antibiotics
- **Hard, firm, or matted** consistency of an enlarged lymph node
- Lack of associated infectious symptoms
- **Supraclavicular fossa** location
- Lack of improvement over a 4-week period
- Accompanying constitutional symptoms as previously listed.
- Fluctuance may indicate abscess formation

The above features warrant further investigation even in the acute setting.⁴



MANAGEMENT

Please refer to the flowchart in figure 1 for management of cervical lymphadenopathy in Paediatric setting.

Investigations

No further investigations indicated in:

- Acute <2 weeks duration in well appearing children
- Acute lymphadenitis: Blood tests usually not necessary

If fluctuating in size or small nodes: Reasonable to discharge, advise to return if no regression at 5 days or persistence over 2 weeks.

If larger or non-varying in size or **red flags** (listed above) in exam or history further investigations are warranted to include blood tests + imaging as follows:

<p>First line:</p> <ul style="list-style-type: none"> • Full Blood Count • Liver Function Test • CRP • Serology for EBV and CMV • Blood cultures (if febrile or suspected sepsis/abscess/cellulitis) 	<p>Second line:</p> <p>In addition to first line blood tests, as directed by consultant</p> <ul style="list-style-type: none"> • LDH • Extended serology testing
--	--

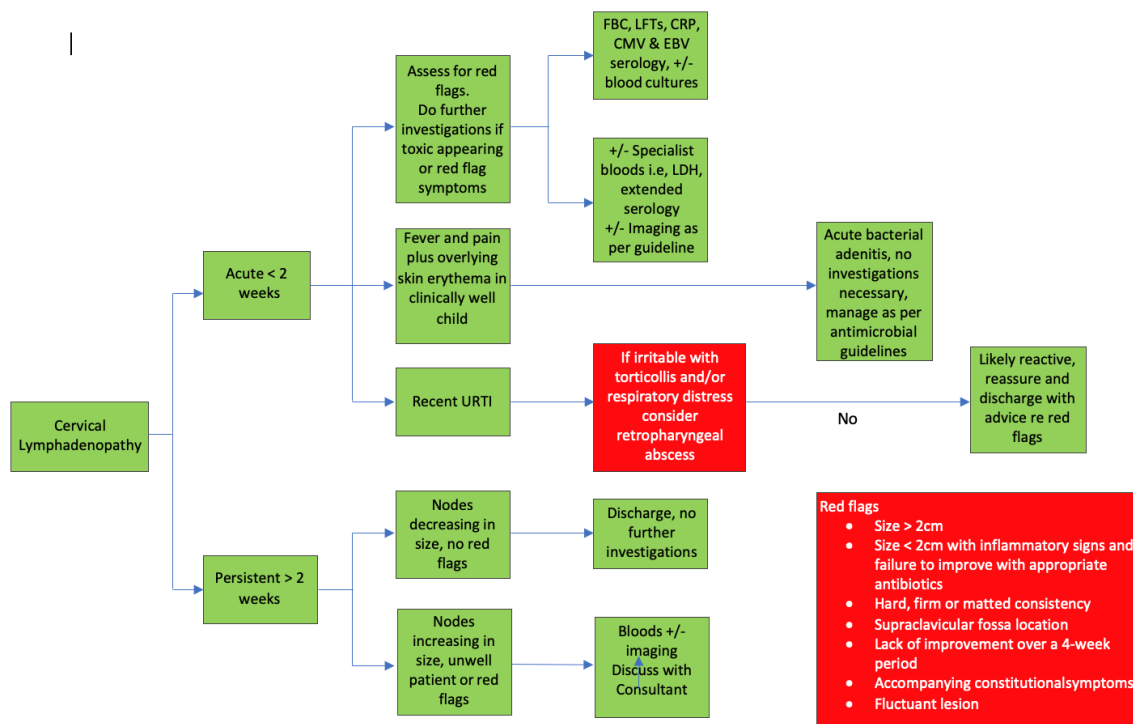


Figure 1: Flowchart of the Management of patient with Cervical Lymphadenopathy

Imaging

- **Ultrasound:** Consider US for red flags, fluctuant node or if indeterminate nodes on clinical exam. Discuss with senior prior to booking ultrasound - early outpatient follow up may be indicated.
- **CXR:** In setting of referral for admission or outpatient review- consider if differential includes malignancy or TB.

If enlarged hilar nodes/suggestive of mycobacterium infection → urgent discussion with respiratory medicine or ID (as per local guidance/policy) for admission and further management.

Consider referral to local paediatric team when:

- Presence of **red flags** or concern regarding underlying pathology.
- If ultrasound shows inconclusive features or suspicious for malignancy, biopsy can be deemed necessary on clinical grounds- referral to oncology.
- If any of below features present refer to ENT for biopsy:
 - i. $\geq 2\text{cm}$
 - ii. History of malignancy or inherent increased risk eg. DiGeorge syndrome
 - iii. Supraclavicular nodes ($>0.5\text{cm}$) (60% of SC nodes are malignant)

Consider ENT referral when:

Abscess formation is suspected as identified by findings of a fluctuant node.

Treatment: Acute Adenitis

Please refer to CHI antibiotic guidance for cervical lymphadenitis:

[CHI Antimicrobial Guidelines 2020](#)

REFERENCES

1. Niezielska G, Kotowski M, Niezielska A, Dybiec E, Wieczorek PP. Cervical Lymphadenopathy in Children- Incidence and diagnostic management. *Int. J Paediatric Otorhinolaryngology*. 71(20070), pp.51-56.
2. RCL CL Guideline accessed on 9th May 2019.
https://www.rch.org.au/clinicalguide/guideline_index/Cervical_lymphadenopathy/
3. Locke, MacGregor et al. The validation of an algorithm for the management of Paediatric Cervical Lymphadenopathy. *International Journal of Paediatric Otorhinolaryngology Volume 81*, February 2016, Pages 5-9.
4. Friedmann, Alison. Evaluation and Management of Lymphadenopathy in children. *Pediatrics in Review* 2008: 29; 53.
5. Geddes, G et al. Pediatric neck masses. *Paediatric Rev* 2013 Mar;34(3):115-24; quiz 125. doi: 10.1542/pir.34-3-115.