

IRISH ASSOCIATION FOR
EMERGENCY
MEDICINE



IAEM Clinical Guideline

**Evaluation and Management of Children
Presenting with Chest Pain to the Emergency
Department**

Version 1.1

September 2024

Author: Dr. James Foley

Guideline leads: Dr. Laura Melody, Dr. Aisling Snow & Dr. Terence Prendiville in collaboration with Clinical Guidelines Development Committee and Children's Health Ireland

To reference this document please reference as:

Foley J. Evaluation and Management of Children Presenting with Chest Pain to the Emergency Department. IAEM Guidelines 2024. <https://iaem.ie/professional/clinical-guidelines/> (accessed 2nd September 2024).

DISCLAIMER

IAEM recognises that patients, their situations, Emergency Departments and staff all vary. These guidelines cannot cover all clinical scenarios. The ultimate responsibility for the interpretation and application of these guidelines, the use of current information and a patient's overall care and wellbeing resides with the treating clinician.

Revision History

Date	Version	Section	Summary of changes	Author
November 2022	V1.0	All	Final Version	JF
September 2024	V1.1	All Front cover Contents	Updated formatting Added guideline referencing information Added table of contents	C. Briant C. Briant C. Briant

CONTENTS

GLOSSARY OF TERMS	4
INTRODUCTION	5
PARAMETERS.....	6
AIMS.....	6
DIFFERENTIAL DIAGNOSIS	7
Table 1. Incidence of chest pain causes as per the literature	7
ASSESSMENT AND MANAGEMENT	8
History.....	8
Figure 1: Chest Pain Algorithm	9
Investigation	10
SPECIFIC AETIOLOGY AND MANAGEMENT	12
Cardiac pathology	12
Table 2. Cardiac pathology resulting in chest pain	12
Chest Cage and Chest Wall Pain.....	13
Respiratory	14
GI Pathology	14
Non-Organic Disease	14
Miscellaneous.....	15
COMPANION DOCUMENTS.....	16

GLOSSARY OF TERMS

BP	Blood Pressure
CHI	Children's Health Ireland
CTPA	Computed Tomography Pulmonary Angiography
CXR	Chest X-Ray
ECG	Electrocardiogram
ED	Emergency Department
EM	Emergency Medicine
FB	Foreign Body
FBC	Full Blood Count
GI	Gastrointestinal
GORD	Gastro-oesophageal Reflux Disease
NSAIDs	Non-steroidal Anti-inflammatory Drugs
OPD	Out-patient Department
PE	Pulmonary Embolism
V/Q scan	Ventilation/Perfusion Scan

Evaluation and management of children presenting with chest pain to the Emergency Department

INTRODUCTION

Paediatric chest pain is a common presentation to Emergency Departments (EDs). Despite its prevalence, less than 1% of presentations have a cardiac aetiology.¹⁻³ This contrasts with adults, in whom chest pain often reveals a significant cardiac pathology. In children, the diagnosis is usually benign and the most common aetiologies include musculoskeletal, gastrointestinal, pulmonary and idiopathic causes.¹ Extensive public awareness on the association of chest pain and ischaemic heart disease can result in both parents and children assuming that chest pain is likely of cardiac origin.³⁻⁴

Despite the low incidence of significant pathology, paediatric chest pain often leads to unnecessary diagnostic testing and referral to paediatric cardiology services. The purpose of this guideline is firstly to rule out life-threatening conditions which may present and then to form a diagnosis and management plan for the remainder of cases.

PARAMETERS

Target audience: This guide is directed at health-care professionals engaged in the care of paediatric patients presenting to the ED with a chief complaint of chest pain.

Patient population: This evidence summary aims to provide guidance for management of paediatric patients with no known cardiac diagnosis, that present to the ED with chest pain.

AIMS

To provide an evidence-based guideline to assist in the evaluation and management of children with no known cardiac diagnosis, presenting to the ED with chest pain.

DIFFERENTIAL DIAGNOSIS

The differential diagnoses for chest pain and their incidence are shown in Table 1.

Group	Pathogenesis	Incidence
Musculoskeletal		24-56%
Idiopathic		12-52%
Respiratory	Cough Bronchospasm Pleuritic processes (pneumonia / pneumothorax / pulmonary embolus)	7-20%
Miscellaneous	Herpes zoster Sickle cell crisis Tumours (chest wall / mediastinal)	4-11%
Gastrointestinal	Acid reflux Oesophagitis Peptic ulcer disease	3-6%
Non-Organic	Anxiety Hyperventilation	1-9%
Cardiac	Pericarditis / Myocarditis Arrhythmia Myocardial ischaemia (e.g. aortic stenosis, hypertrophic obstructive cardiomyopathy, coronary artery disease)	0.6-1%

Table 1. Incidence of chest pain causes as per the literature 3,5-9

ASSESSMENT AND MANAGEMENT

Please refer to the chest pain algorithm in [Figure 1](#).

History

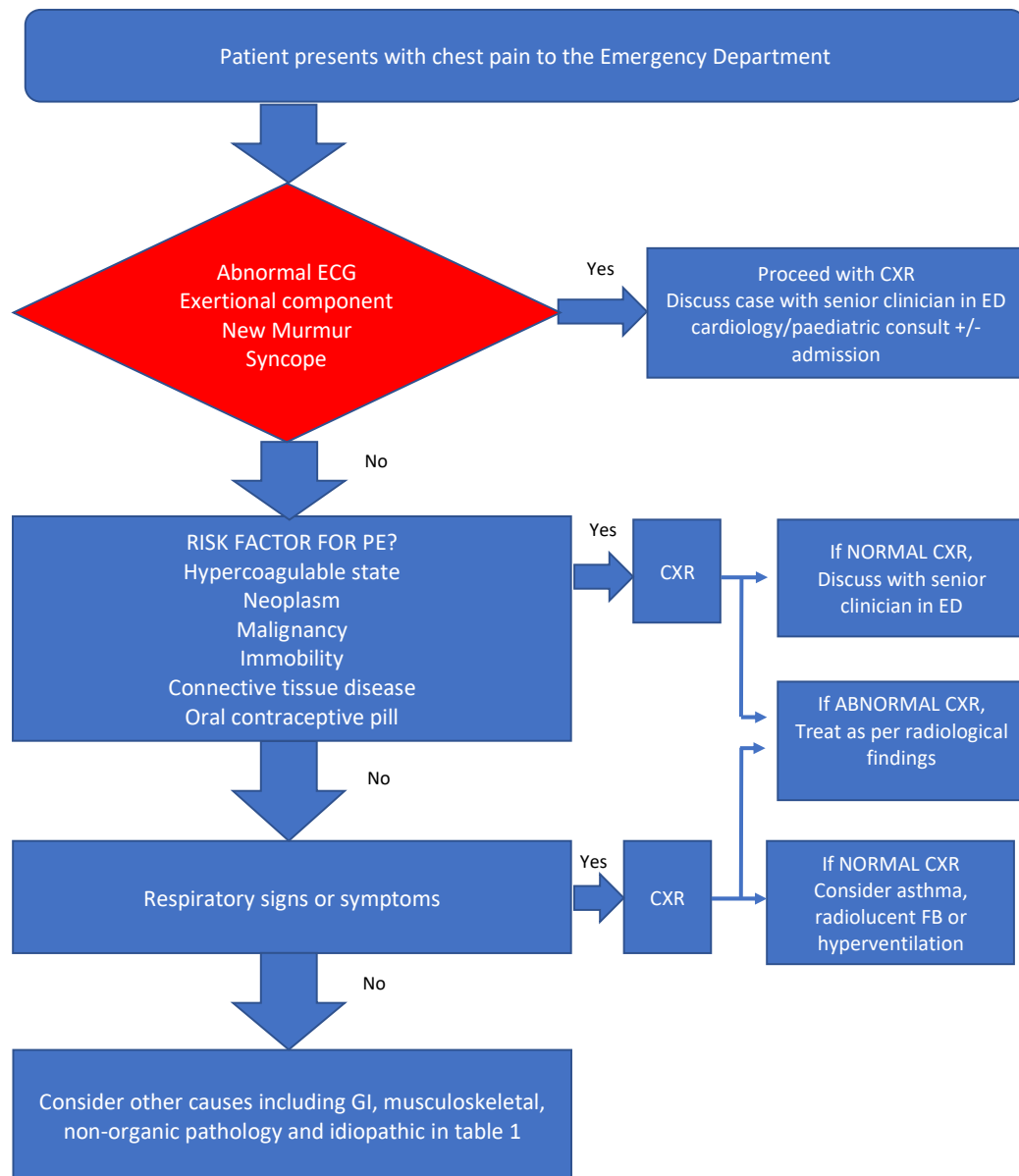
The aetiology of chest pain can often be determined by eliciting a thorough history of the pain and associated features of the presentation. Age should be a consideration when taking the history as adolescents are more likely to present with musculoskeletal or idiopathic pain whereas young children may interpret a wide range of symptoms as pain.⁹

The presence of certain risk factors in the history increases the likelihood of potentially serious causes and should prompt immediate investigation and management. These include:

- Major trauma
- Exertional component / Syncope
- Hypercoagulable states
- Cocaine or stimulant use
- History of connective tissue disease
- Sickle cell disease

All patients should be triaged and given an appropriate triage category as per ICTS. History and examination findings will then help determine which patients should be investigated further.⁹⁻¹¹

Figure 1: Chest Pain Algorithm



Investigation

ECG

An ECG should be performed for all patients who present to the ED with chest pain.

Abnormal findings on the ECG in the patient presenting with chest pain may include:

- ST-segment elevation or depression: *Myocarditis / myocardial ischaemia*
- Saddle-shaped ST elevation: *Pericarditis*
- Sinus tachycardia: *Pulmonary embolus. Myopericarditis*
- Low voltage QRS: *Pericardial effusion from infection, inflammation, or trauma*

All significant abnormal findings should be discussed with a senior EM clinician +/- cardiology on call depending on the findings which can be correlated using the CHI Paediatric ECG guideline which can be found here: [CHI ECG Guideline](#)

Chest X-ray

Indications for a CXR in the history or examination include:

- Cough, fever with signs of pneumonia / pleural effusion on auscultation
- Abnormal cardiac auscultation e.g. new murmur, muffled heart sounds
- Clinical suspicion of pneumothorax / haemothorax
- New onset shortness of breath with pleuritic chest pain
- New exertional dyspnoea with chest pain
- [History of drooling or foreign body ingestion](#)
 - A lateral neck x-ray should also be performed for this presentation
 - If the history is suggestive of a foreign body and the CXR is normal, a lateral neck and abdominal x-ray should be performed ¹²⁻¹⁴

A CXR that demonstrates pneumonia, pneumothorax or a foreign body should be managed accordingly.

An enlarged cardiac silhouette may be suggestive of cardiomegaly while a widened mediastinum may be suggestive of adenopathy, mediastinal mass or rarely, an aortic dissection. These findings should be correlated with the clinical presentation and discussed with a senior EM clinician.

If the history and examination is suggestive of a PE, and the CXR is normal, the case should be discussed with a senior EM clinician and a decision made regarding further investigations.

Blood tests

Laboratory tests are usually not helpful in determining the aetiology in paediatric chest pain.¹⁵⁻

¹⁶ In specific circumstances where conditions such as myocardial ischaemia, pulmonary embolism, myocarditis, pericarditis, pneumonia, or pancreatitis are suspected, blood tests may be useful. The utility of laboratory tests will be determined by the history, examination, and specific findings on ECG or CXR if applicable.

SPECIFIC AETIOLOGY AND MANAGEMENT

Cardiac pathology

The cardiac causes of chest pain are displayed in Table 2. Cardiac disease is more likely if chest pain occurs during exertion, results in syncope or is recurrent. There should be an abnormal examination in these patients, and in patients with known cardiac disease, chest pain may indicate progression of the underlying condition.³

Table 2. Cardiac pathology resulting in chest pain 3

Cardiac cause of chest pain	Pathophysiology
Pericarditis	Chest pain due to pericarditis is usually caused by infection or inflammation. The pain is usually acute, located over the anterior chest wall and more severe than other forms of chest pain. It can be exacerbated by deep breaths. The pain may decrease in severity when the patient is upright and leaning forward.
Tachyarrhythmias	Supraventricular tachycardia with, or without underlying Wolff-Parkinson-White Syndrome. Ventricular Tachycardia.
Severe left ventricular outflow tract obstruction	Caused by aortic stenosis, obstructive cardiomyopathy or coarctation of the aorta.
Aortic root dissection	Associated with Marfan syndrome, Turner syndrome, Ehlers-Danlos syndrome, chronic systemic hypertension, homo-cystinuria, rare familial aortopathies or cystic medial necrosis.
Coronary artery abnormalities	Congenital disorders such as Anomalous origin of coronary artery Acquired conditions such as Kawasaki disease.
Ruptured sinus of Valsalva aneurysm	Rare condition, caused by congenital absence of media in the aortic wall behind the sinus of Valsalva. Rupture of the aneurysm into the right ventricle or atrium, leads to intra-cardiac shunting and myocardial ischaemia.

Referral to Paediatric Cardiology

Follow up arrangements are determined by the final diagnosis. Most paediatric patients who present with chest pain will not need follow-up, but should the following risk factors be present, admission or referral to Cardiology OPD should be considered. This should be discussed with a senior EM clinician or paediatrician and if during working hours, could be discussed with the cardiology team on the same day.

The following conditions warrant discussion with General Paediatrics +/- Cardiology:

- Exertional-type chest pain
- Exercise-induced syncope or pre-syncope
- Abnormal ECG
- Potentially inherited cardiac disease
- Abnormal cardiovascular examination ⁹

Chest Cage and Chest Wall Pain

Musculoskeletal or chest wall pain is the most common cause of chest pain in children and adolescents with its prevalence estimated between 15 and 31%.^{5,17,18}

Management of musculoskeletal pain encompasses reassurance, a brief period of rest and analgesia.¹⁸ Counselling patients about the benign nature of the condition helps to reduce the degree of concern surrounding the chest pain. Prescribing a course of NSAIDs and recommended warm compresses to the affected area may be a helpful treatment strategy.

Respiratory

Reversible airways disease can present as chest pain initially and a thorough history eliciting a family history of atopy, breathlessness during exercise, exertional cough or wheezing episodes may point to asthma being the cause of the chest pain.

Other respiratory causes of chest pain that should be considered include pneumothorax, lower respiratory tract infection, foreign body, and pulmonary embolism.

GI Pathology

In cases where the pain is related to eating or there are other symptoms of reflux, a GI cause such as GORD, gastritis or oesophagitis should be considered. Specifically, the presence of reflux or heartburn symptoms should be elicited at the time of clinical presentation and can be quite specific in the diagnosis of GORD.^{3,11} If tender on abdominal palpation, consideration should be given to pathology such as biliary disease or pancreatitis depending on the history.¹¹

Non-Organic Disease

Chest pain can occasionally result from anxiety triggered by recent stressors in personal or family life and is often associated with other somatic complaints and sleep disturbance.^{17,18}

Patients who present to ED because of non-organic pathology should be discussed with a senior clinician. It is unlikely that these patients have serious illness and will not require any further investigations. Reassurance and stress relief should be encouraged. If there is any concern regarding self-harm or suicidal intent, these patients should be considered for urgent psychiatric review.

Miscellaneous

Herpes zoster infection (Shingles)

Herpes zoster infection of the chest wall may present with significant chest pain. It is usually in a dermatomal pattern and can precede the rash by a few days. The treating doctor should manage the patient's pain accordingly and advise further review should a rash appear in the following days.

Spinal cord compression

Children with deformities of the spine including scoliosis are susceptible to nerve root or spinal cord compression and may complain of chest pain as the first symptoms. These patients should be reviewed by an orthopaedic surgeon for further evaluation and treatment.¹⁸

COVID-19 Vaccination and Chest Pain

Globally, an increased number of cases above an expected population rate of myocarditis and pericarditis have been reported in individuals who have received mRNA COVID-19 vaccines (Comirnaty™/BioNTech/Pfizer and Spikevax/Moderna). Cases usually occur after second dose of an mRNA COVID-19 vaccine and within 0-14 days of vaccine administration.

Healthcare professionals should consider myocarditis or pericarditis in any child who presents with new onset of shortness of breath, palpitations, and acute chest pain, who has recently received a dose of an mRNA COVID-19 vaccination. An ECG and troponin should be performed and if abnormal, or if normal with high clinical suspicion the case should be discussed with a cardiologist. If low suspicion, and investigations are normal, the child can be discharged to their General Practitioner.

COMPANION DOCUMENTS

- [References](#)
- [Parent information leaflet](#)