

IRISH ASSOCIATION FOR
EMERGENCY
MEDICINE



IAEM Clinical Guideline

Periorbital and Orbital Cellulitis (Adults and Paediatrics)

Version 2.1

August 2024

Authors: Dr Ken Au Yong, Dr Karen Harris

Reviewed by: Mr Tim Fulcher, Consultant Ophthalmic Surgeon

To reference this document please reference as:

Au Yong K Harris K. Periorbital and Orbital Cellulitis. IAEM Guidelines 2024.
<https://iaem.ie/professional/clinical-guidelines/> (accessed 27th August 2024).

DISCLAIMER

IAEM recognises that patients, their situations, Emergency Departments and staff all vary. These guidelines cannot cover all clinical scenarios. The ultimate responsibility for the interpretation and application of these guidelines, the use of current information and a patient's overall care and wellbeing resides with the treating clinician.

Revision History

Date	Version	Section	Summary of changes	Author
March 2022	V1.0	All	Final version	KAY/KH
April 2022	V2.0	Glossary Introduction Parameters	Updated after review by Consultant Ophthalmic Surgeon	KAY/KH
August 2024	V2.1	All Front cover Contents References	Updated formatting Added guideline referencing information Added table of contents Added references to main document	C. Briant C. Briant C. Briant C. Briant

CONTENTS

GLOSSARY OF TERMS	4
INTRODUCTION	5
Image 1: Diagram illustrating the location of the orbital septum [1].....	5
PARAMETERS.....	7
AIMS.....	7
ASSESSMENT	8
SAMPLE IMAGES OF PRESEPTAL AND ORBITAL CELLULITIS	9
INVESTIGATIONS.....	9
MANAGEMENT.....	10
REFERENCES	11

GLOSSARY OF TERMS

CNS:	Central nervous system
ED:	Emergency Department
RAPD:	Relative Afferent Pupillary Defect
IV	Intravenous
FBC	Full Blood Count
CRP	C-reactive Protein
ENT	Ear, Nose and Throat
CT	Computed Tomography
PO	Per Os (by mouth)
Children:	Patients aged from birth – date of 16 th birthday
Adults:	Patients aged 16 years and older

Periorbital and Orbital Cellulitis

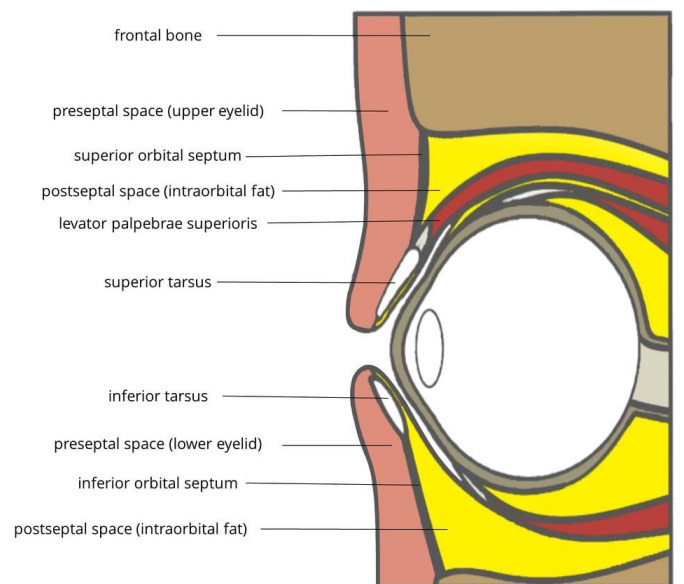
INTRODUCTION

Periorbital and orbital cellulitis describe infections of the soft tissues surrounding the globe of the eye. This term covers 2 distinct clinical entities, namely:

- a. **Periorbital (Pre-septal) cellulitis**, i.e. infection anterior to the orbital septum.
and
- b. **Orbital (Post-septal) cellulitis**, i.e. infection posterior to the orbital septum.

The orbital septum is a fibrous tissue layer that extends from the periosteum of the orbital rim into the eyelids and provides an effective physical barrier against the spread of infection.

Image 1: Diagram illustrating the location of the orbital septum [1]. Image used under Creative Commons use policy.



T. Fahrnhorst-Jones
2021

Radiopaedia

Periorbital (Pre-septal) cellulitis is an infection confined to the anterior of the orbital septum. It can be caused by local spread from an existing eyelid or periocular infection eg. stye, chalazion, dacryocystitis etc., trauma or upper respiratory tract infection.

Orbital (Post-septal) cellulitis occurs when the infection breaches the orbital septum or occurs posterior to it. The majority of cases originate from local paranasal sinus infection, but can also rarely be caused by trauma, intra-orbital foreign body or haematogenous spread. This condition represents an emergency as it can lead to serious complications including loss of vision, cerebral sinus thrombosis and CNS infection.

PARAMETERS

Target audience: Clinical staff working in an ED /acute paediatric assessment facility involved in the assessment of children or adults presenting with suspected periorbital or orbital cellulitis

Patient population: Any patient presenting with features of suspected periorbital or orbital cellulitis. Infected eyelid lesions or dacryocystitis are amongst the most common causes of pre-septal cellulitis and may need to be treated in the same way as mild pre-septal cellulitis.

Exclusion criteria: Patients presenting with other localised eye infections e.g. blepharitis/conjunctivitis.

AIMS

The aim of this document is to provide guidance to clinical staff involved in the first line assessment and management of adults and children presenting with features suggestive of periorbital or orbital cellulitis.

ASSESSMENT

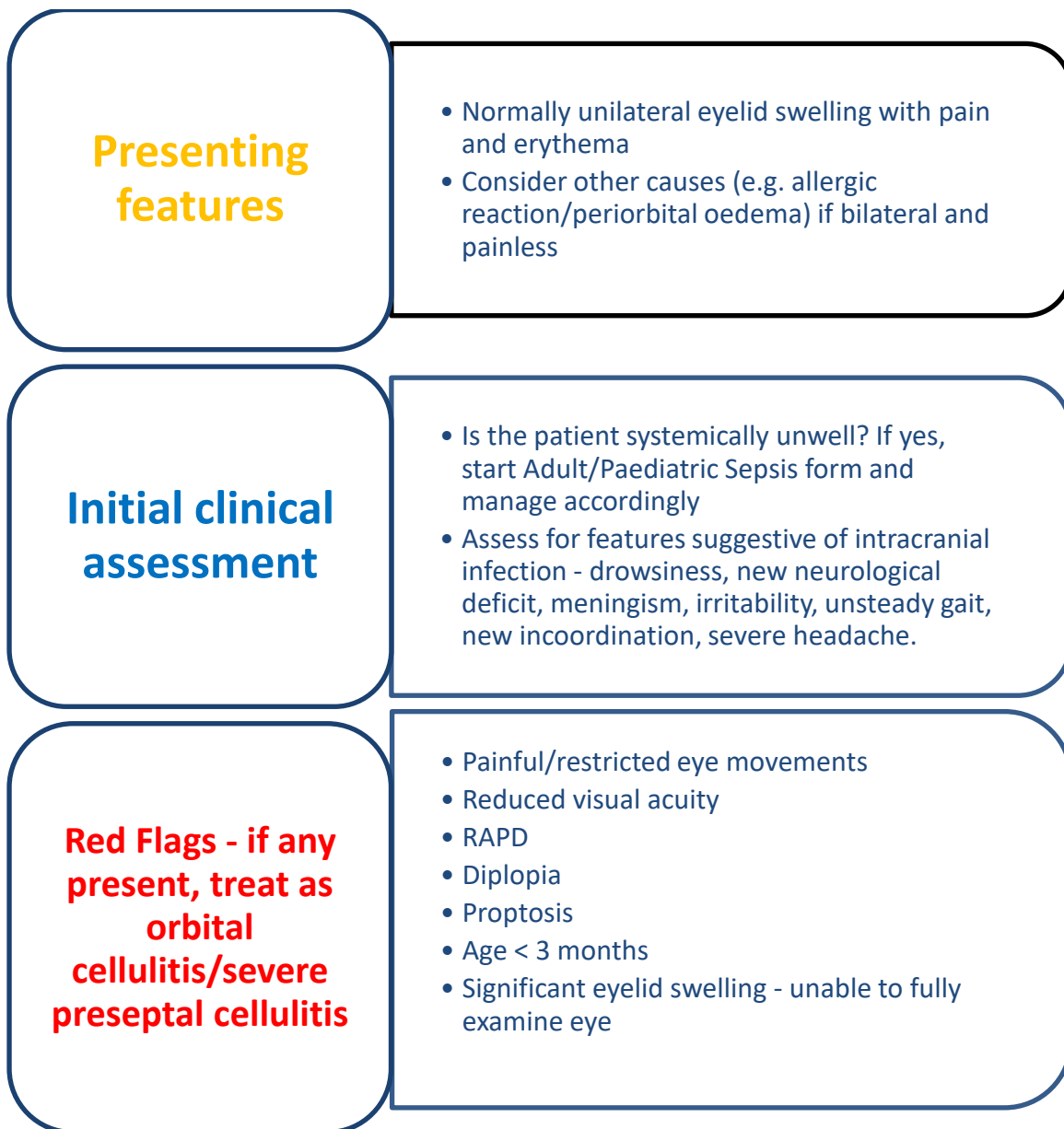


Figure 1: Suggested assessment flow for patients presenting with suspected periorbital cellulitis

If no evidence of sepsis/intracranial infection/red flags; assess for **features of mild peri-orbital (pre-septal) cellulitis**. **All criteria must be met.**

- Minimal swelling
- Able to fully examine eyes
- Sclera is white
- Normal eye movements
- Systemically well, afebrile

SAMPLE IMAGES OF PRESEPTAL AND ORBITAL CELLULITIS

Please note that the images below are a representation of the features of pre-septal and orbital cellulitis. They should not be relied upon solely to reach a diagnosis and each patient should be comprehensively evaluated clinically and with radiological studies as indicated.

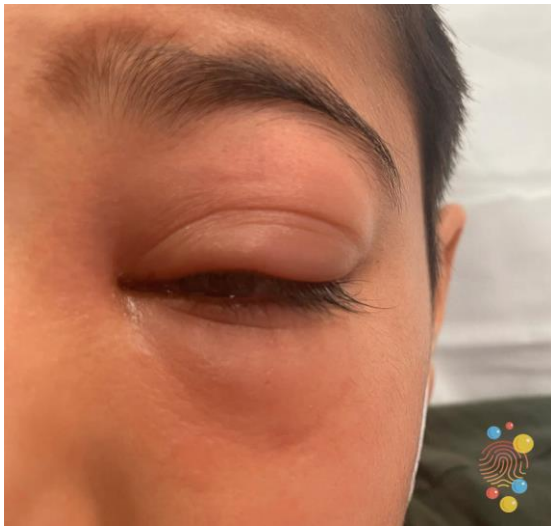

Image 2: Periorbital (Pre-septal) cellulitis [2]. Permission for use kindly granted by DFTB Skin Deep.

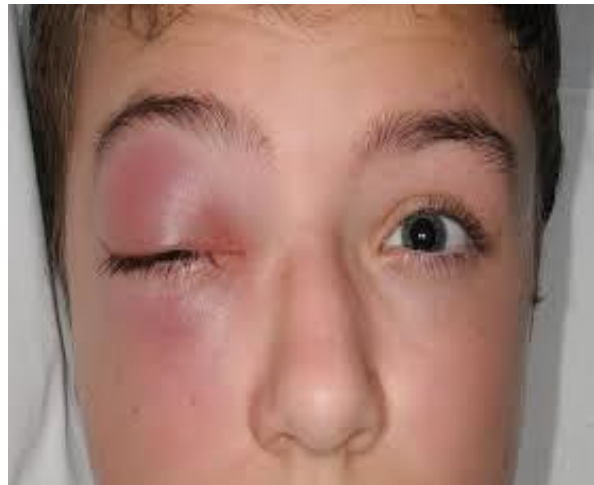

Image 3: Orbital (post-septal) cellulitis [3]. Licence for use granted by the BMJ Publishing Group.

INVESTIGATIONS

Mild periorbital (pre-septal) cellulitis: None required

Patient with presence of 'red flags':

- IV access- Blood cultures, FBC, Renal profile, CRP
- Nasal swab for culture and sensitivity (or sinus swab if endoscopy planned by ENT team)
- Neuroimaging (contrast enhanced CT of Orbits, Sinuses +/- Brain)

MANAGEMENT

	Children (Per CHI guidelines): https://www.olchc.ie/healthcare-professionals/clinical-guidelines/antimicrobial-guidelines-2021.pdf	Adults
Mild periorbital (pre-septal) cellulitis	PO Co-amoxiclav or PO Cefalexin for 10-14 days	Refer to local antimicrobial guidelines
	Ensure adequate analgesia, safety netting (advise on features of Red Flags in Figure 1 above)	
Severe periorbital (pre-septal) cellulitis	IV Cefotaxime OR IV Ceftriaxone	Refer to local antimicrobial guidelines
Orbital cellulitis suspected or confirmed on imaging	IV Cefotaxime OR IV Ceftriaxone and IV Metronidazole	Refer to local antimicrobial guidelines

Table 1: Suggested antimicrobial management of periorbital infections

In patients requiring IV antibiotics, ensure:

- a. Urgent Ophthalmology and ENT consult.
- b. Children: Admission under General Paediatrics / ENT (depending on local resources and arrangements)
- c. Adults: Admission under Ophthalmology / ENT (depending on local resources and arrangements)
- d. Commencement of intranasal decongestant (Xylometazoline – dosing per BNF) if sinusitis is suspected as the source of infection
- e. 4 hourly eye (visual acuity, pupils and colour vision) and neuro-observation

REFERENCES

1. Fahrenhorst-Jones, T: Orbital septum (diagram)[Internet]. Radiopaedia.org; 2021 Aug 31. [Cited 2021 Oct 3]. Available from: <https://radiopaedia.org/cases/orbital-septum-diagram-1?lang=us>
2. [Periorbital diffuse swelling with mild erythema] [Image on the Internet]. [London]: DFTB Skin Deep; ?2020 [cited 2021 Nov 29]. Available from: <https://dftbskindeep.com/all-diagnoses/periorbital-cellulitis/>
3. Harris MS, Chawdhary G. A swollen right eye in a child. *BMJ* 2015 Feb 5;350:h554. Periorbital swelling of the right eye [image];p.1.[cited 2022 Mar 2]. doi: 10.1136/bmj.h554
4. British Society for Antimicrobial Chemotherapy [Internet]. Birmingham: British Society for Antimicrobial Chemotherapy; 2021. Pre-Septal and Postseptal (Orbital) Cellulitis Pathway for Children Presenting to Hospital; [cited 2021 Sep 25]; [about 2 screens]. Available from: <https://bsac.org.uk/paediatricpathways/preseptal-orbital-cellulitis.php>
5. The Royal Children's Hospital Melbourne [Internet]. Melbourne: Royal Children's Hospital; 2021. Periorbital and Orbital Cellulitis; 2019 Jul [cited 2021 Sep 24]; [about 4 screens]. Available from: https://www.rch.org.au/clinicalguide/guideline_index/Periorbital_and_orbital_ccelluliti/
6. Aslam, Willmott, Woodruff. Preseptal and Orbital Cellulitis UHL Children's Hospital Guideline [Internet]. Leicester: University Hospitals of Leicester NHS Trust; 2020. [cited 2021 Sep 24]. Available from: <https://secure.library.leicestershospitals.nhs.uk/PAGL/Shared%20Documents/Preseptal%20and%20Orbital%20Cellulitis%20UHL%20Childrens%20Hospital%20Guideline.pdf>
7. Williams KJ, Allen RC. Paediatric Orbital and Periorbital Infections. *Curr Opin Ophthalmol*. 2019 Sep; 30(5):349-55.
8. Mahalingam S, Hone R, Lloyd G, Grounds R, Shamil E, Wong G, et al. The management of periorbital cellulitis secondary to sinonasal infections: a multicenter prospective study in the United Kingdom. *Int Forum Allergy Rhinol*. 2020 Jun;10(6):726-37.
9. Children's Health Ireland. Antimicrobial Guidelines 2020 [Internet]. Dublin: Children's Health Ireland; 2021. [cited 2021 Sep 28]. Available from: <https://www.olchc.ie/healthcare-professionals/clinical-guidelines/antimicrobial-guidelines-2021.pdf>
10. Tsirouki T, Dastiridou AI, Ibanez flores N, Cerpa JC, Moschos MM, Brazitikos P, et al. Major Review: Orbital Cellulitis. *Surv Ophthalmol*. 2018 Jul-Aug;63(4):534-53.